

## **Role of Bisphenol and Vitamin C in Liver Toxicity: Experiment of Wistar Rats**

**Kajol Agarwal**

*Lecturer, Krishna Institute of Medical Science, Karad, India*

**Dr. Raveena Shetti**

*Department of Bio Sciences, Krishna Institute of Medical Science, Karad, India*

### **Abstract**

Bisphenol A (BPA) is considered one of the most common industrial manufactured chemicals that is toxic to the various tissues including liver. Vitamin C is an important dietary antioxidant which significantly decreases the adverse effects of reactive oxygen species. This study was conducted to evaluate the damaging effect of Bisphenol on liver and the role of vitamin C on Bisphenol induced liver damage. Animals were divided into the following groups with 6 rats in each group; Group 1: Control Group (Olive oil treated), Group 2: (Vitamin C treated), Group 3: (Bisphenol treated), Group 4: (Vitamin C + Bisphenol treated). Liver tissue was processed to measure MDA and GSH level, serum SGPT, SGOT and ALP level in all the four groups. Histological slides were done to assess the changes in the liver. Results of the present study showed that there was decrease in the liver tissue level of GSH and increase in MDA, SGPT, SGOT and ALP. Treatment with Vitamin C showed a significant increase in testicular GSH level, decrease in SGPT, SGOT and ALP as well as good response for histological damage. Thus we have hypothesized that vitamin C could act as an antioxidant against BPA induced oxidative stress. Vitamin C is an endogenous water soluble antioxidant. Results of the present study showed there was significant increase in the tissue level of GSH in the rats co-administered with BPA and vitamin C.

### **Keywords:**

Bisphenol-A, oxidative stress, testosterone, Vitamin C

### **Article History:**

Received: 19th May 2022

Accepted: 25th Jun 2022

Published: 14th Jul 2022

## **1. INTRODUCTION**

Bisphenol A (BPA) is one of the environmental contaminants widely used in the manufacture of polycarbonate plastic (example: water and baby bottles), inside coating in metallic food cans (Barnham K.J., 2004). Humans are at an increasing risk of exposure to BPA since it can leach out of polymers and enter food and water sources (Barnham K.J., 2008 & Rubin B.S., 2011). BPA causes liver damage, thyroid disorder, diabetes mellitus type –II and pancreatic damage. BPA has been shown to dysregulate the cytokines and induce oxidative stress in the brain, liver, and kidney (Gonzalez-Parra E., 2013 & Kabuto, H 2004). BPA is known to cause tissue injury in the liver, kidneys, brain and other organs by forming oxidative stress (Gonzalez-Parra E., 2013 & Kabuto, H 2004). Oxidative stress has long been linked with pathogenesis of various diseases in humans. Reactive oxygen species (ROS) are cytotoxic agents that lead to damage of nucleic acid bases, lipids and proteins, thereby leading to cell death. Some findings also indicate an involvement of oxidative stress and mitochondrial dysfunction to the damaging effect of BPA (E. Carchia, I., 2012). The generation of oxygen radical is balanced by the presence of adequate endogenous antioxidant defense mechanism. Antioxidant compounds can prevent the uncontrolled formation of free radicals or inhibit their reaction with biological sites. The destruction of most free radicals depends on the oxidation of endogenous antioxidants mainly by scavenging and reducing molecules. Vitamin E, vitamin C, and  $\beta$ -carotene are known as antioxidant vitamins that are suggested to decrease oxidative damage and lowering the risk of certain chronic diseases. Vitamin C is an important dietary antioxidant which significantly decreases the adverse effects of reactive oxygen species implicated in chronic diseases including neurodegenerative diseases. So present study was aimed to evaluate the damaging effect of Bisphenol on liver and to evaluate the

role of vitamin C on Bisphenol induced liver damage

## 2. MATERIALS AND METHODS

Animals: Institutional ethics committee clearance was obtained before beginning the experiments. Healthy adult Albino rats of wistar strain approximately 150-200gm body weight, aged 2-3 months was procured from the central animal house of our institution. They were housed in the central animals' house at the laboratory under controlled conditions of temperature and light with normal rat feed and drinking water.. Bisphenol A (CAS NO:80-05-7, CAT No: 31817 -Sisco company) and Ascorbic acid (CAS No: 50-81-7- Merck company) was purchased from Sri.Durga Laboratories, Mangaluru, India. Animals were divided into the following groups with 6 rats in each group:

Group 1: Control Group (Olive oil given orally for 3 weeks.)

Group 2: ((Experimental control)) VitaminC(60mg/kgbw/day) dissolved in distilled water treated orally for 3 weeks

Group 3: (Bisphenol treated) Bispenol(25mg/kgbw/day) dissolved in olive oil given orally for 3 weeks

Group 4: (Vitamin C + Bisphenol treated group) treated with vitamin C (60mg/kg bw/day) along with Bispenol (25mg/kg bw/day) for 3 weeks

After desired protocol, animals were anesthetized by giving Pentobarbitone (40mg/kg bw) . Blood samples were collected from the heart with the help of a 2-ml syringe for measuring serum SGPT, SGOT and ALT level in all the four groups. A part of the tissues was used for estimation of GSH (Ellman GL,1959) and MDA level in all the groups (Rao GM,2000)

Five micron thick sections were obtained by Rotary microtome (Lieca company) and cut sections were floated in warm water in a tissue flotation bath and then mounted on the glass slide and dried for a day (Culling C F A,1985). Then the slides were stained using haematoxylin and eosin stains. Finally, a drop of Canada balsam in xylol was placed on the slide and covered with a cover slip. Slides were coded and analysed (Banchroft J D1990).

## 3. STATISTICAL ANALYSIS

The data was expressed as mean  $\pm$  SEM. Analysis was done by using the unpaired t test. Statistical package SPSS version 17.0 was used to do the analysis. P<0.05 was taken as significant

## 4. RESULTS

**Table 1:** Effect of vitamin C treatment on liver tissue level of GSH and MDA .Values are expressed as Mean $\pm$ SEM. Number of animal (n)=6. P <0.05 is taken as significant. NS(non-significant) GR.I versus GR.II & GR.III versus GR.IV \*\*\*P<0.0001,GR.I versus GR.III, ¶¶¶P<0.0001, GR.III versus GR.IV

**Effect of vitamin C treatment on bisphenol(BSA) induced liver damage:**

GROUPS	GSH((ug/g tissue)	MDA (microgram/gm tissue)
--------	-------------------	---------------------------------

GR.I	991.28± 75.62	18.48± 0.25
GR.II	1181.33± 46.45 <sup>NS</sup>	16.43± 0.95 <sup>NS</sup>
GR.III	613.83± 27.2 <sup>***</sup>	22.40± 0.94 <sup>***</sup>
GR.IV	981.38± 39.65 <sup>***</sup>	20.27± 0.57 <sup>NS</sup>

Results of the present study showed that there was a significant(P<0.0001) decrease in the liver tissue level of GSH and an significant(P<0.0001) increase in MDA level after the administration of bisphenol (25mg/kg bw/day) when compared to normal control group and vitamin C treated group(Gr.I and Gr.II) . Treatment with Vitamic C showed a significant increase in liver GSH level (Gr.IV) compared to bisphenol intoxicated rats(Gr.III). But, Vitamin C treatment(Gr.IV) there was decrease in MDA level (Gr.IV) but it was not statistically significant compared to only bisphenol treated rats(Gr.III) (Table-1)

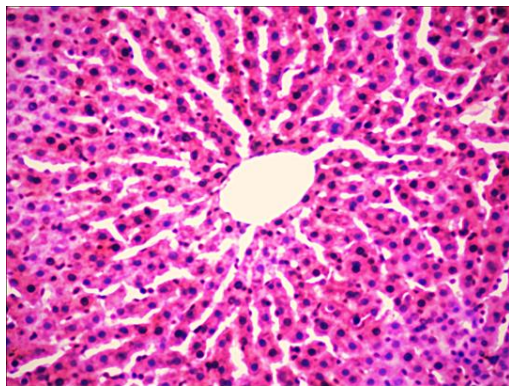
**Table 2:** Effect of Vitamin C on serum biochemical hepatic markers in BPA-intoxicated rats.. Values are express as Mean±SEM. Number of animal (n=6). P <0.05 is taken as significant. NS(non-significant) GR.I versus Gr.II & GR.III versus GR.IV \*\*\*P<0.001,GR.I versus GR.III

GROUP S	SGOT(U/L)	SGPT(U/L)	ALP(IU/L)
GR.I	115.66±2.25	43.66±2.87	85.5±3.01
GR.II	116.5± 1.51 <sup>NS</sup>	42.16±1.60 <sup>N</sup> s	87±1.67 <sup>NS</sup>
GR.III	195.33± 2.42 <sup>***</sup>	85.5±4.03 <sup>***</sup>	118.5±3.88 <sup>*</sup> **
GR.IV	186.16±4.83 <sup>N</sup> s	72.66±8.82 <sup>N</sup> s	117±4.098 <sup>NS</sup>

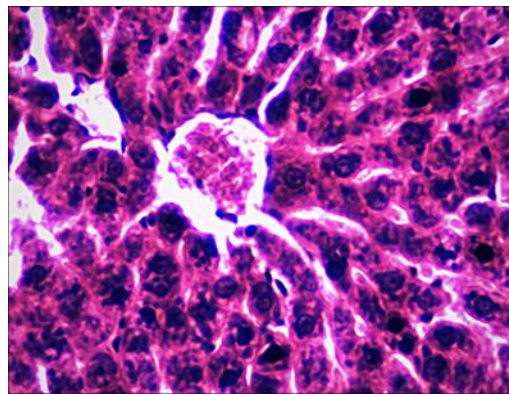
Results of the present study showed that there was significant(P<0.001) increase in the level of SGPT and SGOT and ALP in bisphenol treated group (Gr.III) compared to Gr.I and Gr.II. When the rats were treated with vitamin C in bisphenol intoxicated rats there was decrease in the level of SGPT,SGOT and ALP but it was not statistically significant compared to bisphenol toxicated rats (Table-2).

***Histological results of the liver:***

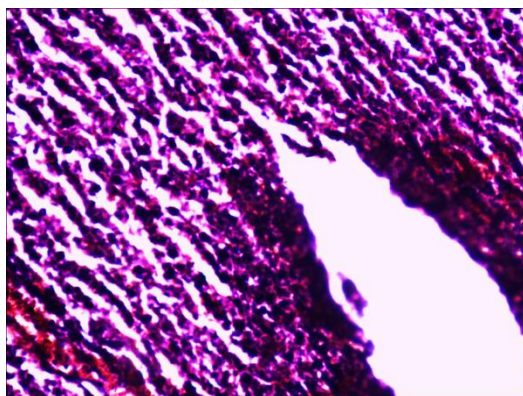
Liver section in normal control rats(Gr.I) and vitamin C treated rats showed normal heaptocytes, sinusoids and portal traidis (Figure:1 & 2). But, in the bisphenol treated rats (Gr.III) the liver histology showed loss of normal architecture with enlarged central vein and sinusoids with lot of infiltration (Figure:3). The photomicrograph of the rats treated with vitamin C(Gr.IV) showed reduced infiltration & improved architecture of hepatocytes along with the sinusoids arranged like that of normal liver cells (Figure:4)



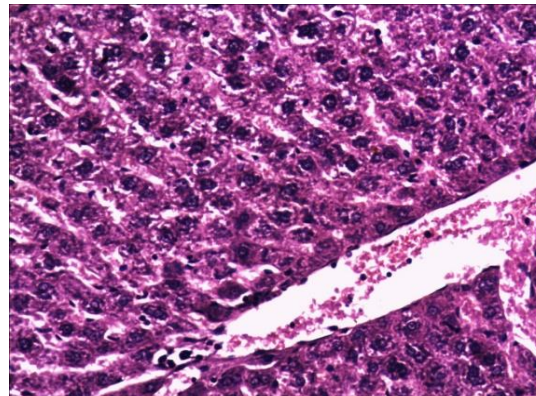
**Figure 1: Photomicrograph of liver of control animal showing single cell thick liver cells, normal sinusoids, and portal triad (PT)(Gr.I). (Haematoxylin & Eosin.)**



**Figure 2: Photomicrograph of liver of Vitamin C treated animal showing single cell thick liver cells, normal sinusoids, and portal triad (PT) (Gr .II). (Haematoxylin & Eosin.)**



**Figure 3: Photomicrograph of rat liver treated with bisphenol showing hepatocytes have lost their normal architecture with enlarged central vein and sinusoids with lot of infiltration and inflammation (Gr.III). (Haematoxylin & Eosin)**



**Figure 4: Photomicrograph of liver of treated with vitamin C in bisphenol toxicated rats showing reduced infiltration & improved architecture of hepatocytes (Gr.IV). (Haematoxylin & Eosin)**

## 5. DISCUSSION

Bisphenol A (BPA) has become a target of intense public scrutiny since concerns about its association with human diseases such as obesity, diabetes, reproductive disorders, and cancer (Barnham K.J., 2004). BPA is a highly prevalent chemical in consumer products, and human exposure is thought to be ubiquitous. The results of the present study showed that administration of bisphenol (25mg/kg bw/day) showed a significant decrease in the tissue level of GSH. This indicated the tissue damage induced by bisphenol. The body cells have numerous defence mechanisms against oxidative stress, including enzymatic scavengers (such as SOD, CAT and GSH) that protect the system from deleterious effects of ROS. Our study revealed that BPA caused marked oxidative impact by decreasing the activities of GSH compared to their activities in the control group. These data are in agreement with the previous results (Chitra et al, 2003) who illustrated that treatment of rats with BPA increases levels of ROS production. Also, other results of (Karafakioglu et al, 2010) evidenced that concentrations and activities of antioxidant enzymes significantly decreased in rats after nonylphenol administration.

SGPT and SGOT are the liver specific enzyme. Acute liver injury is known to cause high levels of SGPT and SGOT (Reyers F, 2003). Serum SGPT and SGOT are the most sensitive markers of liver damage because they are cytoplasmic in location and are released into the circulation after hepatocellular damage (Sharma R.K., 1997). The results of the present study also showed an increase in the level of liver enzymes like SGPT, SGOT and ALP. An increase in the level of hepatic specific enzymes indicated the liver damage induced by bisphenol A.

In consistent with the mentioned data, we observed histopathological changes in the liver indicating variable damage due to exposure to BPA. Our microscopic results are in accordance with studies reported by several authors (Pari L, 2005 & Boshra, V, 2011). In present study; it has been observed that exposure to BPA rats showed that liver sections which had lost their normal architecture with enlarged central vein and sinusoids with lot of infiltration and our results are in accordance with of previous findings that reported that BPA causes cell infiltration and necrosis (Roy, S, 2011 & Verma, R.J, 2009), vacuolated hepatocytes and liver damage (Hanioka, 2008). Previous study has shown that Vitamin C scavenged hydroxyl radicals and prevented lipid peroxidation in the cell membrane (Dogan, A, 2005). But in contradiction, results of the present study showed that vitamin C administration did not statistically decrease the MDA level in all the liver. It is known that vitamin C has prooxidant effects. With this ability, vitamin C can reduce metals to forms that react with oxygen to form lipid peroxidation initiators (Prat, A.G, 1990 & Rekha D Kini, 2011). So, these results may also be explained with pro-oxidant properties of vitamin C.

## 6. CONCLUSION

The results of the present study showed that vitamin C could act as an antioxidant against BPA induced oxidative stress.

## References

1. Bancroft J D, Stevens A. 1990. Theory and practice of histological techniques, 3rd edition, London, Churchill Livingstone
2. Barnham K.J., Masters C.L., Bush A.I. 2004. Neurodegenerative diseases and oxidative stress. *Nat. Rev. Drug Discov.* 3(3):205–214.
3. Boshra, V., Moustafa, A.M., 2011. Effect of pre ischemic treatment with feno fibrate, a peroxisome proliferator-activated receptor alpha ligand, on hepatic ischemia-reperfusion injury in rats. *J.Mol. Hist.* 42, 113–122.
4. Calafat AM, X. Ye, L. Y. Wong, J. A. Reidy, and L. L. Needham, 2008. "Exposure of the U.S. population to bisphenol A and 4-tertiary-octylphenol:" *Environmental Health Perspectives*, vol. 116, no. 1, 39–44
5. Carchia, I. Porreca, P. J. Almeida et al. 2012. "Evaluation of low doses BPA-induced perturbation of glycemia by toxicogenomics points to a primary role of pancreatic islets and to the mechanism of toxicity," *Cell Death and Disease*, vol. 6, no. 10, article e1959
6. Chitra, K.C., Rao, K.R., Mathur, P.P., 2003. Effect of bisphenol A and co-administration of bisphenol A and vitamin C on epididymis of adult rats: a histological and biochemical study. *Asian J. Androl.* 5, 203–

- 208.
7. Culling C F A, 1985. Allison RT, Batt WT. Cellular pathology techniques,14th edition, London: Butter worths,
  8. Dogan, A., Kolankaya, D., 2005. Protective effect of Anzer honey against ethanolinduced increased vascular permeability in the rat stomach. *Exp. Toxicol. Pathol.*57, 173–178.
  9. Ellman GL. Tissue sulfhydryl groups. 1959. *Arch Biochem Biophys.*;82(1):70-77
  10. Gonzalez-Parra E., Herrero J.A., Elewa U., Bosch R.J., Arduan A.O., Egidio J. 2013. Bisphenol a in chronic kidney disease. *Int. J. Nephrol.* 43:78-82
  11. Hanioka, N., Naito, T., Narimatsu, S., 2008 Human UDP glucuronosyltransferase isoforms involved in bisphenol A glucuronidation. *Chemosphere* 74, 33–36.
  12. Kabuto, H., Amakawa, M., Shishibori, T., 2004. Exposure to bisphenol A during embryonic/fetal life and infancy increases oxidative injury and causes underdevelopment of the brain and testis in mice. *Life Sci.* 74, 2931–2940.
  13. Karafakioglu, Y.S., Tic, Aslan, R., 2010. Taurine prevents nonylphenol- induced oxidative Stress in rats. *J. Anim. Vet. Adv.* 9 (1), 37–43.
  14. Morgan A.M., El-Ballal S.S., El-Bialy B.E., El-Borai N.B.2014. Studies on the potential protective effect of cinnamon against bisphenol A- and octylphenol-induced oxidative stress in male albino rats. *Toxicol. Rep.*1:92–101
  15. Pari L, Amali DR. 2005. Protective role of tetra hydro curcumin (THC) an active principle of turmeric on chloroquine induced hepatotoxicity in rats. *J Pharm Pharmaceut Sci* 8(1):115-123
  16. Prat, A.G., Turrens, J.F., 1990. Ascorbate- and hemoglobin-dependent brain chemiluminescence. *Free Radic. Biol. Med.* 8 (4), 319–325.
  17. Rao GM, Rao AV, Raja A, Rao S, Rao A. 2000. Lipid peroxidation in brain tumours. *Clin Chim Acta.*;302(1-2):205-211.
  18. Rekha D Kini, Tripathi Y, CV Raghuvver, Sheila R Pai, Ramaswamy C Priya Kamath. Role of vitamin c as an antioxidant in cadmium chloride induced testicular damage. *International Journal of Applied Biology and Pharmaceutical Technology.* 2(3): 2011.484-4887
  19. Reyers F. 2003 Liver Enzyme Profiling: What Works and What Does Not. Proceedings of 28th World Congress of the WSAVA. Bangkok.
  20. Roy, S., Kalita, C.J., Mazumdar, M., 2011. Histopathological effects of bisphenol A on liver of *Heteropneustes fossilis* (Bloch). *Int. Q. J. Environ. Sci. Ecoscan* 1, 187–190.
  21. Rubin B.S. 2011. Bisphenol A: an endocrine disruptor with widespread exposure and multiple effects. *J. Steroid Biochem. Mol. Biol.* 127(1):27–34
  22. Sharma RK. Morphological and morphometric studies on Liver in rats.1997 subjected to repetitive heat stress. *Indian J Med Research.*106: 20-26.
  23. Verma, R.J., Sangai, N.P., 2009. The ameliorative effect of black tea extract and quercetin on bisphenol A -induced cytotoxicity. *Acta Pol. Pharm.* 66, 41–44.